

A Report of Two Cases of “Giant Bartholin Gland Cysts” Successfully Treated by Excision with Review of Literature

ANJI REDDY KALLAM¹, VANDANA KANUMURY², NAVEENA BHIMAVARAPU³, BHAVIKA SOORADA⁴

ABSTRACT

Bartholin's gland cysts are one of the common vulval masses that may start as asymptomatic cysts but if left untreated, may become large and infected requiring medical attention. We are presenting two interesting and rare cases of giant Bartholin cyst and their treatment in this case report. Two female patients of perimenopausal age presented with giant vulval cysts to the outpatient department of Obstetrics and Gynaecology. They reached a size of 10 cm and 20 cm diameter respectively, presenting with some diagnostic and later reconstruction of the labia majus. MRI pelvis provided good information regarding the size, shape and extent of the cyst, which was very useful during surgery. Both these cases were successfully treated by excision of the cyst and histopathological examination after complete excision. One of the cases presented as dumb-bell shaped swelling with large cyst superiorly and smaller cyst extending into the buttock connected by narrow neck and showed cross fluctuation. This type of dumb-bell shaped presentation of Bartholin's cyst is rather unusual and has not been reported in the available literature.

Keywords: Bartholin cyst, Female reproductive system, Labial cyst, Labial swellings

CASE 1

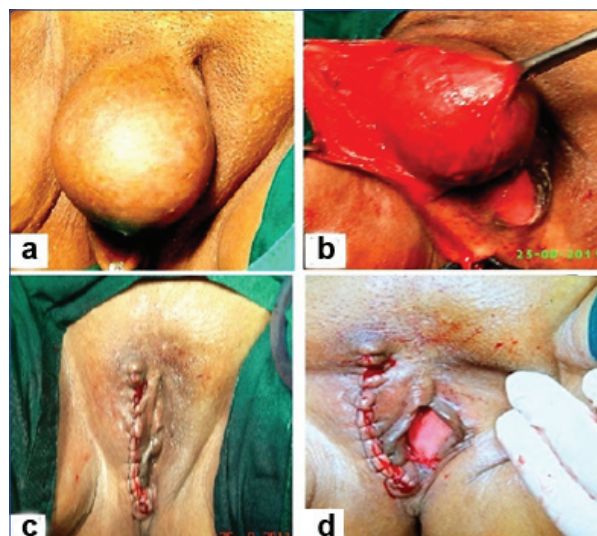
A 68-year-old, postmenopausal woman was referred to plastic surgery department from the department of obstetrics and gynaecology with complaint of swelling in the right labial region present approximately over the last two years. It was small and painless, gradually increasing in size. More rapid increase in size was observed over the last three months.

On clinical examination, there was a solitary swelling situated in the right labium majus extending from the level of pubic bones down to just above the vulval fourchette inferiorly. A swelling of size 10 x 7 x 3 cm was noted, which was a soft but tense swelling with a smooth surface with no tenderness or local warmth. It was subcutaneous, extending deep into tissue planes. Fluctuation was present. Transillumination was negative. No enlargement of regional lymph nodes. A clinical diagnosis of Bartholin gland cyst was made and planned for surgical excision.

Under spinal anaesthesia, with patient in lithotomy position and a urethral foley's catheter in situ, an elliptical vertical incision was made and the skin flaps were reflected. The large cystic swelling was exposed and separated by blunt and sharp dissection on all sides and completely excised. There was nearly 500 ml of thick straw coloured fluid in the cyst. The resultant defect in the right vulvar region was repaired in two layers.

The excised tissue was sent for histopathological examination. Cut section of the tissue showed uniloculated cyst with a smooth inner surface which was greyish brown in colour. Microscopic examination showed the cyst lined by cuboidal to columnar epithelium and the cyst wall showed chronic inflammatory cell collections. Suggestive of infected Bartholin cyst with haemorrhage.

Postoperative period was uneventful and the patient recovered fast and was discharged on seventh postoperative day after removing the sutures. She was comfortable and doing well when she came for check up after three weeks. There was no report of recurrence over the last five years [Table/Fig-1].



[Table/Fig-1]: a) Preoperative; b) Perioperative; c) After excision of the cyst; d) Post-operative.

CASE 2

A 42-year-old woman came with chief complaint of large swelling near the introitus on the right side since one and half years which grew suddenly over the last six days to the present size. Patient gave a history of fever five days prior, which was associated with chills and rigors. She was a known diabetic since one year and was on medication. There was no history of any trauma, weight loss or loss of appetite.

On examination, there were two masses one at right labia majora (23 x 11 cm) and one just below it at the right gluteal region (6 x 6 cm). Both the swellings were cystic in consistency with cross fluctuation present between the two. Transillumination was negative and getting above the swelling was absent. Per speculum and bimanual examination were normal [Table/Fig-2].

MRI pelvis was done and the report showed evidence of very large thick walled (6 mm) bilobed heterogenous cyst, arising from the

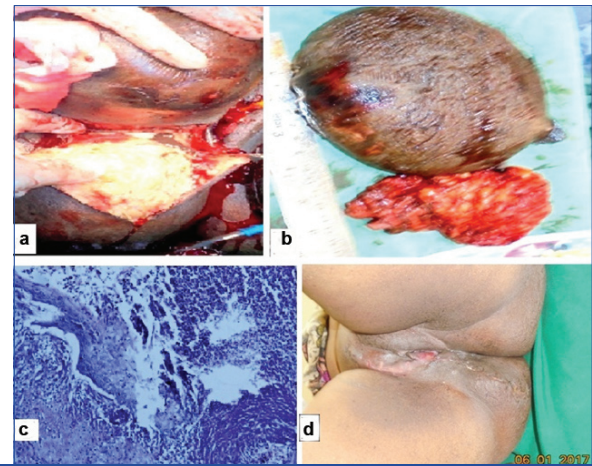
right vulval region below the level of pubic symphysis, anterior lobe- 14.2 x 10.6 x 13.5 cm; posterior lobe 7.3 x 7.6 x 8.3 cm extending postero-infero-medially upto proximal one third of right thigh [Table/Fig-3].

Patient was taken up for surgery. A vertical elliptical incision was made around the base of the cyst 1 inch away from labia and 2 inches away from anal opening. Cyst with false capsule was dissected and separated by blunt and sharp dissection on all sides. The labial cyst was excised and found to be having dark stained thick fluid; the gluteal cyst was also isolated and separated and removed in toto. Levator muscles repaired and skin was closed with 4-0 Prolene [Table/Fig-4a,b]. The excised cyst along with its extension was sent to the department of pathology for histopathological examination.

On gross examination, larger specimen of size 23 x 11 x 9 cm weighing 1500 gm: wrinkled skin with altered blood with a wall thickness of 1.5 cm; and also a smaller specimen which was a fibrofatty mass partly covered by skin of 9 x 7 x 5 cm.

Microscopic examination showed stratified squamous epithelium with underlying cyst and cyst wall showed extensive denudation of serosa. The wall was thickened and infiltrated by predominantly acute inflammatory cells. Areas of haemorrhage and congested blood vessels were also noted [Table/Fig-4c].

During the postoperative period patient was put on antibiotic coverage and suture removal was done on seventh postoperative day. Wound healed well and was discharged with satisfactory result [Table/Fig-4d].



[Table/Fig-4]: a) Peroperative image showing cyst separation; b) Gross specimen; c) Photomicrograph (H&E, X 40) cyst lined by squamous epithelium with inflammatory cells in the wall; d) Postoperative.

The most common types of Bartholin gland masses are cysts or abscesses [2]. Bartholin gland cysts develop from dilatation of the duct following blockage of the duct opening. An obstructed Bartholin duct can become infected and form an abscess. Abscesses are three times more common than cysts [2,3]. Women in the reproductive age group are likely to develop Bartholin abscess. Abscesses appear most likely in women at risk for sexually transmitted infections [4]. The infection is usually polymicrobial, with bacteroides and *Escherichia coli* being predominant organisms [5,6].

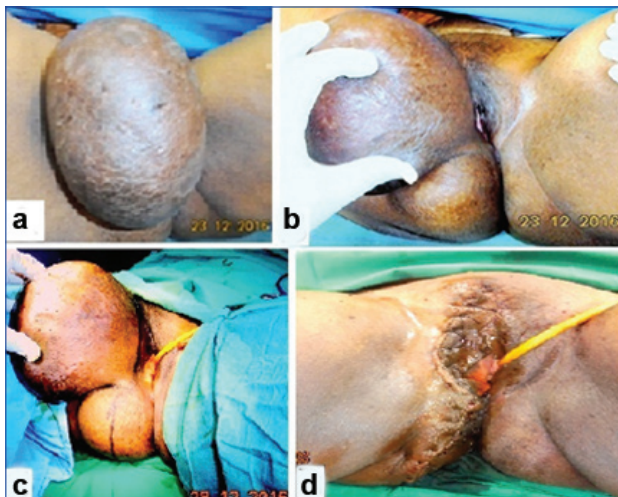
Bartholin cysts usually do not cause any symptoms, but abscesses can present with severe pain and can cause discomfort, typically during ambulation, sitting or sexual intercourse (dyspareunia). Fever may or may not be an associated feature [7]. On examination it appears as a warm, tender, soft, fluctuant mass in lower medial labia majora and may occasionally be surrounded by erythema and oedema. Large abscesses may expand into the upper labia. Other conditions that may mimic Bartholin's abscess include hidradenitis suppurativa, lipomas, epidermoid cysts and Skene's duct cysts [8,9]. The key to identify a Bartholin mass is the anatomic location of the mass [10].

In addition to physical examination, high definition ultrasound and MRI is helpful in aiding a diagnosis [11-13].

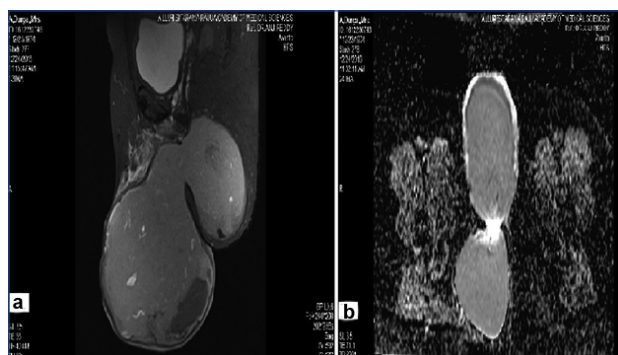
The initial treatment is incision and drainage with placement of Word catheter [14]. Immediate pain relief occurs upon drainage of pus. The catheter is left inside for 4-6 weeks for epithelization. Similarly, the Jacobi ring can also be used for drainage and re-epithelization of the cysts. In a randomized study on treatment of Bartholin cysts, outcomes using Jacobi rings and word catheter were comparable, but rings have a greater patient satisfaction. In the same study, 4%-17% presented with recurrence after using catheter insitu, and often there were cases of premature dislodgment of the catheter before the tract is epithelialized [15]. For deep cysts and abscesses, this treatment is not advisable [16]. However, antibiotics are not given routinely, because more than 80% of cultures from Bartholin's cysts and about 33% of cultures from Bartholin's abscesses are sterile.

Another common method of treatment for Bartholin glands cysts is marsupialization where a small 1.5 cm to 3 cm incision is given over the cyst allowing drainage of the secretions [17]. But in the presence of an abscess, marsupialization should not be performed. In a randomized prospective study, out of 83 women submitted to marsupialization, the most frequent postoperative symptoms were discharge at the surgical site and labial oedema and also 24.1% presented with recurrence, 68.7% had scar formation [18].

Other methods of treating Bartholin gland cysts or abscesses include silver nitrate application, CO₂ laser vaporization, and needle aspiration with or without alcohol sclerotherapy and gland excision.



[Table/Fig-2]: a) Preoperative; b) Showing dumb-bell appearance; c) Peroperative; d) Postoperative.



[Table/Fig-3]: a) MRI of the cyst b) MRI showing dumb-bell appearance.

DISCUSSION

Bartholin's glands, the female counterpart of the Cowpers glands in the male, are compound racemose glands lined by columnar epithelium. Each gland measures about 0.5 cm, with a 2 cm duct, opening into the vestibule, in the groove between hymen and labia minora at 5'O and 7'O clock position. Their function is to secrete alkaline mucous for lubrication during sexual stimulation [1].

In randomized prospective study comparing marsupialization and silver nitrate application in management of Bartholin cyst and abscesses, both seem to be equally effective, however, with silver nitrate, complete healing with less scar formation was observed [18].

In a study in 2012 on management of Bartholin cysts with CO₂ laser vapourization, out of 127 patients, only 86.6% cured after a single laser treatment. The mean cyst size in the study was ranging from 1.5 cm to 5.0 cm [19]. However, management of bigger size cysts with CO₂ laser ablation has not been mentioned in literature.

In a systematic review in 2009, authors concluded that all of the available treatments were associated with lesser recurrence rates, faster healing, and few adverse events. However, best treatment approach for these bigger size cysts could not be identified according to the current literature [20].

Although giant Bartholin's cyst is reported in several case reports, dumb-bell shaped presentation has not been reported in literature. In our cases marsupialization, CO₂ laser ablation, sclerotherapy are not feasible because of the bigger size of the cysts. So we managed the cases with excision and pelvic floor repair with subsequent good outcome in both the cases. Thus, excision of the entire Bartholin gland and duct is the definitive procedure of treatment for these cases.

CONCLUSION

Though Bartholin's cyst abscess presents as a vulval mass, a dumb-bell shaped presentation or as a giant cyst, as in our cases are very rare. Management modality of these may be altered from that of a normal presentation according to the amount of discomfort it causes to the patient and size and extent of the mass. Though physical examination and MRI help in making a diagnosis, biopsy is confirmatory. Surgical management with complete cyst excision under antibiotic coverage is the definitive treatment.

ACKNOWLEDGEMENTS

We sincerely acknowledge the help rendered by the faculty of the radiodiagnosis, anaesthesiology and pathology department of ASRAM Medical College and Hospital for their valuable help extended during the management of these patients.

REFERENCES

- [1] Hoffman BL, Schorge JO, Bradshaw KD, Halvorson LM, Schaffer JI, Corton MM. Williams Gynaecology, 2016, p280.
- [2] Antvorskov JC, Josefsen K, Engkilde K, Funda DP, Buschard K. Dietary gluten and the development of type 1 diabetes. *Diabetologia*. 2014;75:1770–80.
- [3] Omole F, Simmons BJ, Hacker Y. Management of Bartholin's duct cyst and gland abscess. *Am Fam Physician*. 2003;68:135–40.
- [4] Aghajanian A, Bernstein L, Grimes DA. Bartholin's duct abscess and cyst: A Case-Control study. *South Med J*. 1994;87(1):26.
- [5] Brook I. Aerobic and anaerobic microbiology of Bartholin's Abscess. *Surg Gynaecol Obstet*. 1989;169(1):32.
- [6] Tanaka K, Mikamo H, Ninomiya M, Tamaya T, Izumi K, Ito K, et al. Microbiology of bartholin's gland abscess in Japan. *J Clin Microbiol*. 2005;43(8):4258.
- [7] Kessous R, Aricha-Tamir B, Sheizaf B, Steiner N, Moran-Gilad J, Weintraub AY. Clinical and Microbiological characteristics of Bartholin's gland abscesses. *Obst Gyn*. 2013;122(4):794.
- [8] Koenig C, Tavassoli FA. Nodular hyperplasia, adenoma, and adenomyoma of Bartholin's gland. *Int J Gynecol Pathol*. 1998;17:289–94.
- [9] Kessous R, Aricha-Tamir B, Sheizaf B, Steiner N, Moran-Gilad J, Weintraub AY. Clinical and microbiological characteristics of Bartholin gland abscesses. *Obstet Gynecol*. 2013;122:794–99.
- [10] Sosnik H, Sosnik K, Halon A. The pathomorphology of Bartholin's gland. Analysis of surgical data. *Pol J Pathol*. 2007;58:99–103.
- [11] Kozawa E, Irisawa M, Heshiki A, Kimura F, Shimizu Y. MR findings of a giant Bartholin's duct cyst. *Magn Reson Med Sci*. 2008;7:101–03.
- [12] Berger MB, Betschart C, Khandwala N, De-Lancey JO, Haefner HK. Incidental bartholin gland cysts identified on pelvic magnetic resonance imaging. *Obstet Gynecol*. 2012;120:798–802.
- [13] Eppel W, Frigo P, Worda C, Bettelheim D. Ultrasound imaging of Bartholin's cysts. *Gynecol Obstet Invest*. 2000;49:179–82.
- [14] Marzano DA, Haefner HK. The Bartholin's gland cyst: Past, Present and Future. *J Low Genital Tract Disease*. 2004;8(3):195.
- [15] Gennis P, Li SF, Provataris J. Randomized pilot study comparing a rubber ring catheter to the word catheter in the treatment of Bartholin abscesses. *Acad Emerg Med*. 2004;11(5):527.
- [16] Koc O, Sengul N, Gurel S. Perineal leiomyoma mimicking complex Bartholin mass. *Int Urogynecol J*. 2010;21:495–97.
- [17] Bora SA, Condous G. Bartholin's , vulval and perineal abscesses. *Best Pract Res Clin Obstet Gynaecol*. 2009;23(5):661-66.
- [18] Ozdegirmenci O, Kayikcioglu F, Haberal A. Prospective randomized study of marsupialization versus silver nitrate application in the management of bartholin gland cysts and abscesses. *J Inim Invasive Gynaecology*. 2009;16(2):149-52.
- [19] Figueiredo ACN, Folgado da Silva PA, Duarte AR, Gomes TPM, Borrego LMP, Marques CAC. Bartholin's gland cysts: management with carbon-dioxide laser vaporization. *Rev Bras Ginecol Obstet*. 2012;34(12):550-54.
- [20] Wechter ME, Wu JM, Marzano D, Haefner H. Management of Bartholin duct cysts and abscesses: a systematic review. *Obstet Gynecol Surv*. 2009;64:395–404.

PARTICULARS OF CONTRIBUTORS:

1. Director and Plastic Surgeon, Department of Plastic Surgery, ASRAM Medical College, Eluru, Andhra Pradesh, India.
2. Professor and Head, Department of Obstetrics and Gynaecology, ASRAM Medical College, Eluru, Andhra Pradesh, India.
3. Postgraduate Student, Department of Obstetrics and Gynaecology, ASRAM Medical College, Eluru, Andhra Pradesh, India.
4. Postgraduate Student, Department of Obstetrics and Gynaecology, ASRAM Medical College, Eluru, Andhra Pradesh, India.

NAME, ADDRESS, E-MAIL ID OF THE CORRESPONDING AUTHOR:

Dr. Anji Reddy Kallam,
 Director and Plastic Surgeon, Department of Plastic Surgery, ASRAM Medical College, Eluru-534004, Andhra Pradesh, India.
 E-mail: reddykanji@gmail.com

FINANCIAL OR OTHER COMPETING INTERESTS: None.

Date of Submission: **Jan 17, 2017**
 Date of Peer Review: **Mar 28, 2017**
 Date of Acceptance: **Apr 17, 2017**
 Date of Publishing: **Jun 01, 2017**